



Document heading

## Assessment of Specificity and Sensitivity of Tru-Cut Biopsy as Compared with Postoperative Histopathological Results in Young Females with Breast Mass

Fatima Mutasher Swadi

College of Medicine University of Kerbala.

<https://orcid.org/my-orcid?orcid=0000-0001-7611-0343>

Corresponding author

E-mail address: [Fatimahisto78@gmail.com](mailto:Fatimahisto78@gmail.com)

### Article Info.

#### Article history:

Received 05 September 2022

Revised 12 November 2022

Accepted 1 January 2023

#### Keywords:

Assessment of specificity and sensitivity, Tru-cut biopsy Breast mass

#### How to cite:

Fatima Mutasher Swadi. Assessment of specificity and sensitivity of tru-cut biopsy as compared with postoperative histopathological results in young females with breast mass. *Int J Med Sci.* 2023;3(1):16-23. <https://doi.org/10.56981/M313>

#### Copyright:

© 2023 MESPIJ-Publishers. All rights reserved.

### Abstract

Breast cancer affects 5-7% of 25-39-year-olds, and early detection increases the chance of recurrence (CBC). African- American women under the age of 40 had the highest rate of breast cancer. After breast cancer radiation and family history, younger persons are more likely to get colon cancer. Some women misdiagnose breast symptoms as cancer due to fear and stress. A clinical examination cannot distinguish between benign and malignant tumours.

Stages of treatment the diagnosis decides the treatment. Biopsies and FNAC are used to detect lumps. Plaques. Biopsies of histopathology (CNB) (CNB). OTP biopsy failed. True-cut biopsies minimize the types and grades of malignancy. Bleeds/infects FNAC detects cancer. Cytology is inexpensive. Low sample counts, erroneous negatives, and aggressive tumours According to the study, FNAC assesses breast lumps. False positives and false negatives could be reduced. CNB's results call into question FNAC's mission. CNB. The downsides of CNB include treatment time, patient pain (1.7% to

3.7%), hematoma (0.72%), and pneumothorax. FNAC is less painful and intrusive than CNB for older, weaker patients (more painless). FNAC is not just for radiologists. FNAC examines chemotherapy. Antifreeze. CNB, diagnosis, and anxiety were all improved with FNAC. After neoadjuvant treatment, FNAC reveals tumours, suspicious zones, and a concerning lesion. FNAC replaces mammography.

### Introduction

Breast cancer is a major killer of women in both the developed and developing worlds, and breast disorders are a major source of distress for these women. [1] Breast cancer is estimated to affect between 5% and 7% of women under the age of 40, making it the most common type of cancer among women aged 25 to 39. [2] People who are white and are not of Hispanic origin have the highest rate of breast cancer incidence. When the data is broken down by age, non-Hispanic whites and African Americans between the ages of 30 and 49 have very similar incidence rates. However, African

American females had the highest relative incidence of breast cancer among women under the age of 40. [3]

An earlier diagnosis of breast cancer in either breast is connected with a higher chance of acquiring breast cancer in the other breast (CBC). People under the age of 50 had an overall incidence rate of 0.1% every year for CBC, resulting in a 13% cumulative risk over a 10-year period. A CBC is performed 50% of the time if diagnosed before the age of 45. Radiation treatment after a breast cancer diagnosis, as well as a family history of the disease, have both been linked to an increased risk of colon cancer developing in younger patients. Given the evidence reported here, these patients should be closely monitored after treatment for breast cancer, including imaging of the contralateral breast, despite their young age. [4]

The number of patients with breast lumps is growing. Because of contemporary societal conditions, the proclivity to overlook symptoms, and female patients' reluctance to have experts check for breast lumps. When the disorders worsen or evolve into malignancies, they usually notify the professionals. However, there is a growing awareness among some women who misdiagnose every breast symptom as breast cancer and feel obliged to seek medical attention as a result of the anxiety and stress that comes with it. Clinical examination alone may not always distinguish benign from malignant tumours. [5]

The correct diagnosis based on the disease stage is critical for decision-making in breast cancer cases. The preoperative diagnosis of a breast lump is critical to the overall treatment strategy. Core needle biopsy and fine-needle aspiration cytology (FNAC) are the two most commonly used methods for detecting breast lumps. In recent years, FNAC and CNB have emerged as highly effective diagnostic techniques for assessing palpable breast masses. [6]

Tru-cut biopsy, also known as a core needle biopsy, is a significant approach for obtaining a histological diagnosis today (CNB). It is straightforward and can be done as an outpatient procedure. It also reduces the necessity for unnecessary excisional biopsy. Lower insufficiency rates, the ability to apply ancillary procedures, and the ability to grade and type malignancy are all characteristics of true-cut biopsy that aid in the design of definitive surgery. However, it has significant disadvantages, including discomfort, bleeding, and infection. [7]

It has been repeatedly established that FNAC is an exceptionally useful diagnostic technique for breast masses. It not only saves money but also provides cytological diagnostics in a timely and uncomplicated manner. It does, however, have several limitations, such as the difficulty in distinguishing between invasive and in situ carcinomas, a lack of sufficient sample numbers, and false-negative results. While some research concludes that employing FNAC as a valid screening approach for breast lump inspection is advantageous, others do not. Combining the two methodologies could improve diagnostic output by decreasing the frequency of false positive and false negative outcomes. [8]

### **The Advantages of FNAC Over Core-Needle Biopsy (CNB)**

CNB results appear to be more dependable than FNAC results, which has already raised issues about FNAC's function. CNB is currently utilized rather frequently in the first diagnostic phase. However, there are some drawbacks to CNB, including the time necessary to treat the tissue, the patient's pain (1.7% to 3.7% of cases), hematoma (0.72% of cases), and an exceedingly uncommon pneumothorax. For patients who are elderly or feeble and have multiple medical concerns, FNAC offers more benefits than CNB, such as being less intrusive and causing less discomfort (more painless). Pathologists and other non-radiologists can perform FNAC on palpable tumours with relative ease. The chronological monitoring of the response to neoadjuvant chemotherapy using

FNAC is a promising technique that will almost certainly require regular monitoring. [9]

A critical aspect of FNAC is its ability to provide rapid diagnostic information comparable to that of frozen sections. A rapid FNAC before CNB, according to our observations, resulted in a higher-quality CNB with an immediate diagnosis and reduced patient concern. [10] Multiple tumours or suspicious zones being staged, as well as the advent of a new suspicious lesion while undergoing neoadjuvant chemotherapy, are further indicators of FNAC. When radiographic breast screening is unavailable, FNAC may be an excellent replacement. Table 1 compares the key advantages and disadvantages of FNAC and CNB. [9]

**Table 1** Advantages and disadvantages of FNAC versus CNB.

	FNAC	CNB
<i>General considerations</i>		
a prompt diagnosis	Yes	No
special expertise necessary	Yes	No
Injuries cause pain.	Very low	Low
Rate of complications	Very low	Low
<i>Diagnostic performances</i>		
accurate for microcalcifications or non-palpable lesions	No	Yes
accurate for microcalcifications in masses or palpable lesions	Yes	Yes
Identifying the difference between in situ and aggressive cancer	No	Yes
Low-grade lesions can be distinguished (ADH, papilloma, etc.)	Very difficult	Difficult
Unacceptable sample	High	Low
Immunohistochemistry	Yes	Yes
hybridization in situ	Yes	Yes
Isolation of DNA and RNA for molecular biology	Yes	Yes
uniformity of fixing	Very optimal	Optimal
Cell/tissue bank	Yes	Yes

## Patients and Methods

### Criteria for inclusion

1. Breast lump-bearing women who consent to a mammogram and a tru-cut biopsy of the breast lesion.
2. We only took into account lessons from BIRADS groups 2, 3, 4, and 5.

### Criteria for exclusion

1. Women who just underwent a mammogram and refused to undergo a true-cut biopsy
2. Cases that lacked enough biopsy material were dropped.
3. Situations in which tru-cut biopsies were carried out only without a preceding mammogram.
4. Cases in which a modified radical mastectomy was carried out at the hospital, but a mammogram and tru-cut biopsy were done at another hospital were excluded.

**Movement of patients:** Patients who presented to the General Surgery or Oncology Outpatient Departments with breast lumps were evaluated and referred to the Radiodiagnosis department for a mammogram. A few patients travelled from other hospitals just to receive mammograms. All patients had tru-cut biopsies conducted by the radiologist after their mammograms, and the tissue samples were forwarded to the pathology division.

100 patient who underwent ultrasound-guided interventional procedures provided the data. The

patients were between the ages of 26 and 88. Demographic data, reproductive history, a family history of breast diseases, and a physical examination made up the clinical evaluation.

A qualified radiologist and sonologist from the radiodiagnosis division examined the breast masses with ultrasound technology. Scans were taken both longitudinally and transversely after the transducer was gently applied. The scans provided details on the following four breast characteristics: 3. Width: AP ratio > 1.4 or 1.4; 2. Margins: circumscribed or uncircumscribed; 4. Echogenicity: hyperechoic, isoechoic, or hypoechoic. A diagnosis was made based on these four traits, and the studies were then evaluated and published using the BIRADS technique.

The Core biopsy procedure was carried out with the patient's written consent and was guided by ultrasound by the radiologist.

Each patient received the necessary radiological exams as well as clinical history. Trucut biopsies were conducted in the minor OT by a surgeon, and the biopsy cores were delivered to the Department of Pathology in a formalin container labelled appropriately. Every patient had a FNAC examination performed by a pathologist from the Department of Pathology. After acquiring suitable information, the patients' agreement was obtained for both surgeries.

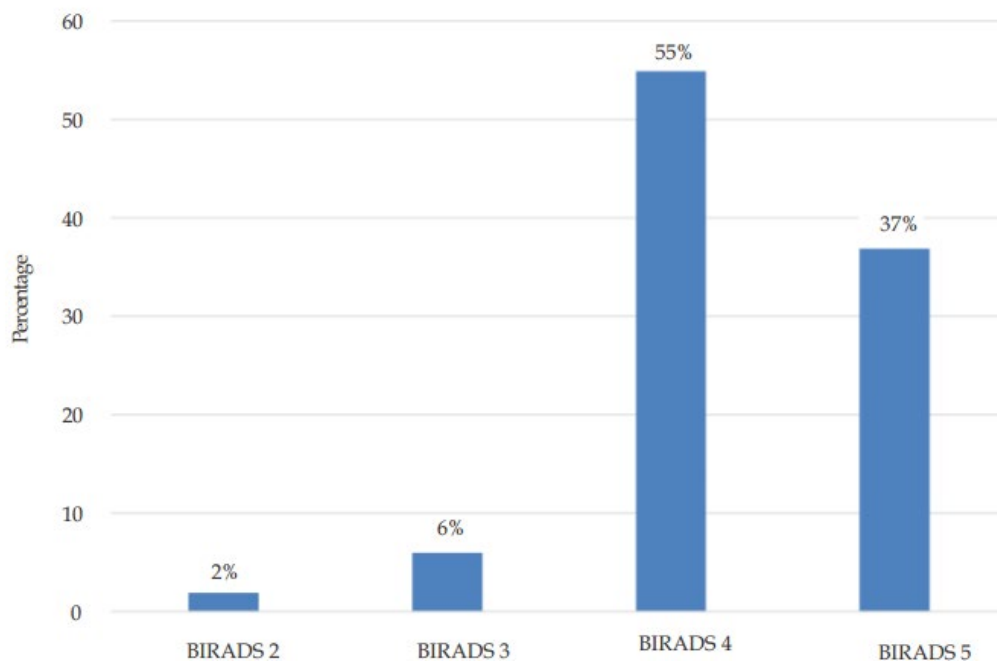
Every patient underwent surgery, and the gross material's histological diagnosis was noted and compared to preoperative diagnostic methods such as FNAC and trucut biopsy. The FNAC smears were stained with H&E and MGG stains, and the results were reported in accordance with the National Health Service Breast Screening Programme criteria (NHSBSP). H&E stains were used to stain the trucut biopsies, and the results were reported in accordance with the standard operating procedure (SOP). A conclusive diagnosis was reached after a histological evaluation of the gross specimen.

## Results

The age distribution of the 100 cases is shown in Table 2. Women in their fifth decade were the age group most likely to participate. The radiological distribution of the lesions under investigation in this study is depicted in Figure 1. Because there are only two women with BIRADS 2 lesions, a true biopsy is not required in this situation; instead, ongoing screening is recommended. BIRADS 2 lesions were found in two of the individuals. Trucut biopsies, on the other hand, were performed in all of these cases due to the patient's concerns and demands. Investigations were conducted on 100 instances, with 100 (55%) classified as BIRADS 4 (55%) and 100 (37%) classified as BIRADS 5 (37%) and 6 (6%) rated as BIRADS 3 (6%), and 2 (2%) classified as BIRADS 2 (2%). Figure 2 depicts the histological distribution of the numerous lesions found during this investigation. A total of 55 BIRADS 4 lesions were recorded, with 24 being invasive ductal carcinoma, NST (no special type), 7 being regular epithelial hyperplasia, 6 being fibroadenoma, 6 being the fibrocystic disease of the breast, 4 being inflammation, 3 being DCIS high grade, and 3 being fibroadenomas. According to a histological investigation, each of the 37 BIRADS 5 lesions was a case of invasive ductal carcinoma. The histopathological examination revealed that four of the six BIRADS lesions included one periductal inflammation, three fibroadenomas, and one case of fibrocystic breast disease. One of the BIRADS 2 lesions was discovered to be a fibroadenoma, and the other to be a papillary carcinoma of the breast. In this particular test, invasive ductal carcinoma was detected in 61 (61%) of the 100 different lesions.

**Table 2** Age-wise distribution of the cases

Age (in years)	No. of cases	Percent (%)
21–30	4	4%
31–40	18	18%
41–50	44	44%
51–60	12	12%
61–70	16	16%
71–80	4	4%
81–90	2	2%
Total	Total 100	100%

**Figure 1** Radiological distribution of results based on BIRADS score**Table 3** Sensitivity and specificity of BIRADS 2, 3 and 5 for malignancy

	Malignant lesions	Benign lesions
Positive cases	True positive - 37	False negative - 01
Negative cases	False positive - 0	True negative - 07

Sensitivity:  $TP/TP+FN \times 100 = 97.5\%$

Specificity:  $TN/TN+FP \times 100 = 100\%$

Diagnostic accuracy:  $TP+TN/TP+TN+FP+FN = 97.7\%$

## Discussion

Breast cancer affects the majority of women. Because breast cancer is the most frequent cancer in women aged 25 to 39, therapy is common and requires special consideration. Although age-related issues may alter their overall care, young patients have the same surgical and medicinal options as the general breast cancer population. These women may have different malignancies and treatment options due to hereditary breast cancer and other risk factors. Breast cancer treatment must include

genetic counsellors and reproductive specialists due to concerns about family and family planning. Young adults are a distinct and complex breast cancer group, necessitating a multidisciplinary approach to their care. Early multidisciplinary care improves surgical, oncologic, and survivorship outcomes due to the complexities and interconnectedness of treatment planning.

Early detection and treatment are the two most important variables in lowering the risk of death from breast cancer. Despite the fact that the most common symptom of breast cancer is the formation of a painless lump, [1] The great majority of breast lumps are noncancerous. The majority of treatment decisions are based on cytological, or tissue-level changes revealed by minimally invasive techniques such as FNAC and CNB, which hold the promise of being exceedingly accurate and closely resembling histology findings. [11]. Imaging techniques should only ever be utilized for screening purposes. In clinical situations, it is impossible to identify which of the two approaches yields more accurate results regarding cytological or tissue-level changes. [12] In recent years, numerous research has attempted to resolve this controversy. Despite this, there is an urgent need for a direct understanding of their individual value in the diagnosis and classification of breast tumours. This necessity is a direct result of the diversity of study outcomes.

CNB outperforms FNAC for detecting whether a breast lump is malignant or borderline. The combined use of the two modalities proved useful in addressing the issue of inadequate specimens, in addition to providing more sensitive and accurate results than either of the two modalities alone. The findings of this study support the notion that both techniques are complementary and that employing them together could improve diagnostic accuracy. [13]

Triple diagnosis (clinical evaluation, mammography, FNAC) is accurate. Yu et al. observed that FNAC has 92.7% sensitivity and 94.8% specificity, except for bad samples. The ROC AUC was 0.986, showing accuracy. FNAC risk is 8% if negative. FNAC accurately evaluates breast cancer if strict criteria are used. They stated FNAC could improve screening and treatment planning. Insufficient FNAC requires CNB to prevent missing a malignant diagnosis. [14] In 408 palpable breast lesions, FNAC with fast identification had 98.1% sensitivity, 89.5% specificity, and 95.8% accuracy, according to Liew et al. Jackman et al. found a 4.4% false negative rate for all lesions, 1.2% for microcalcifications, and 0.8% for tumoral mass. CNB is like FNAC. Most false negative FNACs are due to sampling error or clinical-histological discordance. After an equivocal FNAC, Kooistra et al. recommended CNB for an accurate preoperative diagnosis. [9]

Other authors have concluded that FNAC is straightforward but ineffective for detecting microcalcifications or small lesions that cannot be palpated in situ malignancy. There are preneoplastic lesions that exhibit atypia. Bilous states that CNB is distinguished by atypical proliferative lesions (such as in situ lobular neoplasia and atypical ductal hyperplasia), cellular fibroepithelial lesions, papillary tumours, mucinous carcinoma, radial scars, and spindle cell lesions. Overall, the use of CNB is recommended for the FNAC interpretation. [15]

After core biopsy, all 37 cases of BIRADS 5 lesions that were declared malignant on radiography were found to be malignant. As a result, the BIRADS 5 lesions had a 100% positive predictive value for malignancy. Malignancy is generally more than 95% for lesions in the BIRADS 5 group. According to Selvi Radhakrishna et al., the positive predictive value (PPV) for BIRADS 5 lesions was 93.25%. In a separate study, Kim MJ et al. found that the PPV for BIRADS 5 lesions was greater than 95%. [16]

Core biopsy revealed that 21 of the 55 cases with BIRADS 4 lesions suspected of being carcinogenic based on radiography were benign, whereas 24 were malignant. The probability of cancer for lesions in the BIRADS 4 group ranges from 2% to 95%.



According to our findings, BIRADS 4 lesions showed a 49% positive predictive value for malignancy. This is due to the subdivision of BIRADS 4 lesions into 4A, 4B, and 4C, each of which covers a distinct form of a lesion from the BIRADS 4 classification system, such as inflammatory lesions, breast abscesses, hyperplasias, and many more. The only diagnostic criterion that is specifically specified for subcategorization is a radiologist's or physician's level of suspicion about the presence of malignancy. Eda Elverci and her colleagues<sup>6</sup> discovered that the positive predictive value (PPV) for BIRADS 4 lesions was 38.7% in their study. Sarangan et al.<sup>5</sup> found that the positive predictive value (PPV) for BIRADS 4 lesions was 56.25 per cent in a separate study. If only lesions 4B and 4C are assessed for their histological relationship, the PPV of BIRADS 4 lesions may be higher. This is due to the fact that 4A lesions are not taken into account.

Only one of the eight BIRADS 2 and 3 patients in our study had a malignant lesion, whereas seven of the eight instances were benign, and radiography indicated that they were. The absence of malignancy in BIRADS 2 and 3 lesions exhibited an 87.5% negative predictive value. Following a core biopsy, it was determined that 12.5% of benign and supposedly benign tumours were actually malignant. Sarangan et al.<sup>5</sup> discovered in their investigation that BIRADS 3 had an NPV of 82.92%, which is comparable to the values we obtained. Table 3 shows the results of cancer detection sensitivity and specificity tests performed on BIRADS 2, 3, and 5.

The malignancy diagnostic acuity of BIRADS 2, 3, and 5 was 97.5 percent, 100 percent, and 97.7 percent, respectively. Sarangan et al. discovered that 93.5% of BIRADS were responsive to benign lesions during their examination. According to our findings, BIRADS has a one hundred percent specificity for cancer, which is consistent with previous research findings. BIRADS had a diagnostic accuracy of 97.7% in our study. Numerous studies have shown that the BI-RADS lexicon can help doctors determine the likelihood of breast cancer. It is critical to be aware of different non-breast lesions that may appear as palpable breast masses, such as muscular and pleural lesions.

The fact that many inflammatory breast tumours manifest as palpable lumps, such as duct ectasia and fat necrosis, leads to confusion. Diagnostic mammography may miss a significant proportion of breast cancer patients, particularly in young women with thick breast tissue.

In young women and those with big breasts, mammography appears to be inferior to ultrasonography. [17]

Ultrasound can also be used to guide FNAC or biopsies and is more accurate in assessing dense breast tissue. Some false negative cases are unavoidable with FNAC. According to, false negative results are caused by sampling flaws and interpretation faults. Neither non-proliferative nor inflammatory breast disease increases the likelihood of developing cancer. The western region of Nepal has 18 of the most malignant breast lesions in the 30-50 age group, which is consistent with our findings. Because open biopsy of breast lesions produces more discomfort and sorrow, has a higher rate of wound healing issues, needs a longer recovery time, and is more expensive, Trucut biopsy is recommended.

## Conclusion

Early identification reduces recurrence risk in 5-7% of 25-39-year-olds with breast cancer (CBC). Most breast cancers are in African-American women under 40. Young individuals with breast cancer radiation and family history are more prone to colon cancer. Fear and stress cause some women to misdiagnose breast symptoms as cancer. Exams can't distinguish benign from malignant tumours.

Interventions Diagnosis dictates therapy. FNAC and biopsies find lumps. Plaques. BIOPSY (CNB). OTP biopsy failure. Biopsies decrease cancer. Bleeds/infects FNAC and discovers cancer. Cheap cytology. Low samples, false negatives, aggressive tumours Study: FNAC evaluates breast

masses. False positives and negatives CNB questions FNAC's purpose. CNB. Long treatment periods, discomfort, hematoma, and pneumothorax are drawbacks of CNB. For weaker people, FNAC is less painful and invasive than CNB (more painless). FNAC isn't limited to radiologists. FNAC investigates chemotherapy. Antifreeze. CNB, anxiety, and diagnosis improved with FNAC. FNAC, after neoadjuvant therapy, revealed tumours, suspicious zones, and a lesion. FNAC replaces mammo.

## References:

1. Sung H, Ferlay J, Siegel RL, Laversanne M, Soerjomataram I, Jemal A, et al. Global cancer statistics 2020: GLOBOCAN estimates of incidence and mortality worldwide for 36 cancers in 185 countries. 2021;71(3):209-49.
2. Assi HA, Khoury KE, Dbouk H, Khalil LE, Mouhieddine TH, El Saghir NSJJotd. Epidemiology and prognosis of breast cancer in young women. 2013;5(Suppl 1):S2.
3. DeSantis C, Ma J, Bryan L, Jemal AJCacjfc. Breast cancer statistics, 2013. 2014;64(1):52-62.
4. Reyna C, Lee MCJJomh. Breast cancer in young women: special considerations in multidisciplinary care. 2014;7:419.
5. DeRose YS, Wang G, Lin Y-C, Bernard PS, Buys SS, Ebbert MT, et al. Tumor grafts derived from women with breast cancer authentically reflect tumour pathology, growth, metastasis and disease outcomes. 2011;17(11):1514-20.
6. Tripathi K, Yadav R, Maurya SK. A Comparative Study Between Fine-Needle Aspiration Cytology and Core Needle Biopsy in Diagnosing Clinically Palpable Breast Lumps. Cureus. 2022;14(8):e27709.
7. Ariizumi T, Kawashima H, Yamagishi T, Oike N, Murayama Y, Umezu H, et al. Diagnostic accuracy of fine needle aspiration cytology and core needle biopsy in bone and soft tissue tumour: A comparative study of the image-guided and blindly performed procedure. 2022;59:151936.
8. Bennett IC, Saboo AJWJoS. The evolving role of vacuum-assisted biopsy of the breast: a progression from fine-needle aspiration biopsy. 2019;43(4):1054-61.
9. Garbar C, Curé HJISRN. Fine-needle aspiration cytology can play a role in neoadjuvant chemotherapy in operable breast cancer. 2013;2013.
10. Mondal R, Koley S, Biswas PKJIJoS. Comparative Study Between Intraoperative Fine Needle Aspiration Cytology/Imprint Cytology and Frozen Section in Determination of Tumour Margin. 2018;80(6):554-8.
11. Kar A, Satapathy B, Pattnaik K, Dash PKJJoc. Trucut biopsy vs FNAC of pelvic tumours-who wins the match? 2018;35(3):179.
12. Supriya S, Nirmala C, Raghupathi AJIJoCR, Review. Fine needle aspiration cytology versus core needle biopsy in breast lesions-a comparative study. 2015;7(9):52.
13. Faziludeen S, Sankaran PJIJoR. A belief theory-based decision system for breast cancer data. 2021:1-12.
14. Soni A, Guliani A, Nehra K, Mehta PKJERoRM. Insight into diagnosis of pleural tuberculosis with a special focus on nucleic acid amplification tests. 2022;16(8):887-906.
15. Mahdavi R, Mehrvarz S, Hoseinpour P, Yousefpour N, Abbasvandi F, Tayebi M, et al. Intraradiological pathology-calibrated electrical impedance spectroscopy in the evaluation of excision-required breast lesions. 2022;49(4):2746-60.
16. Chaitanya I, Prabhala S, Annapurna Srirambhatla DAJI. Comparison of histopathologic findings with BIRADS score in Tru-cut biopsies of breast lesions. 2020;9(1):35-41.
17. Kim SH, Kim YSJJoUiM. Ultrasonographic and mammographic findings of male breast disease. 2019;38(1):243-52.